



A Retrospective Comparison Study-Clinical Efficacy of Arthroscopic Treatment in Ischial Tuberosity Cyst

Zhu Mi, Yun Dong

Abstract

Ischial tuberosity cyst is a common disease, and the conventional incision procedure is associated with several disadvantages, leading to unsatisfactory therapeutic outcomes. The aim of the study was to evaluate the clinical outcomes of arthroscopic treatment for ischial tuberosity cyst and compared it with conventional incision surgery.

The clinical data of 57 patients with ischial tuberosity cyst from May 2016 to September 2018 were retrospectively analyzed. According to the inclusion and exclusion criteria, a total of 49 patients were included. Of these patients, 24 patients received arthroscopic procedure (N = 24) and 25 patients received conventional incision procedure (N = 25). The operation time, intraoperative blood loss, postoperative drainage, postoperative hospital stay, and postoperative complications were compared between the 2 groups. Visual analogue scale scores was used to evaluate pain at 1 day, 1 week, and 1 month after the surgery.

All 49 patients were followed up for (11.3 ± 3.3) months. All patients in the arthroscopy group achieved phase I healing while 3 patients in conventional incision group developed complications. The operation time, intraoperative blood loss, postoperative drainage, and hospital stay in the arthroscopy group were (54.7 ± 7.7) minutes, (20.8 ± 3.5) mL, (20.3 ± 5.6) mL, and (2.8 ± 0.6) days, and were significantly better than those of (71.8 ± 8.8) minutes, (67.3 ± 12.0) mL, (103.6 ± 20.3) mL, and (7.8 ± 2.9) days in the conventional incision group, respectively. In the arthroscopy group, the visual analogue scale scores at 1 day, 1 week, and 1 month after the surgery [(2.6 ± 0.7), (0.5 ± 0.6), (0.3 ± 0.5) points] were significantly lower than those in the conventional incision group [(6.0 ± 0.7), (3.0 ± 1.0), and (1.1 ± 1.0) points], and the differences were statistically significant ($P < .05$). Finally, no significant difference was observed in the incidence of postoperative complications between the 2 groups ($P > .05$).

In the treatment of ischial tuberosity cysts, arthroscopy has advantages of minimal invasion, less blood loss during perioperative period, milder postoperative pain, and rapid recovery when compared with conventional incision surgery.

Introduction

Ischial tuberosity cyst is a clinically common disease that is mainly caused by synovitis and bursal effusion of the ischium.^[1] This disease is most commonly found in middle-aged and elderly women. In most of the cases, the cysts appear large due to obscure location, affecting the quality of life of patients. Currently, surgery is still considered as the main treatment method for ischial tuberosity cysts, while conventional incision is associated with disadvantages such as large trauma, high incidences of postoperative wound hematocoele and effusion, incision infection, wound scar healing and other complications, leading to unsatisfactory therapeutic effects of the ischial tuberosity cysts. In recent years, arthroscopic surgical procedure has been rapidly developed. Arthroscopic techniques have been widely reported for the treatment of extra-articular diseases.^[2-4] Nonetheless, although arthroscopy has been attempted for treating ischial tuberosity cysts, only sporadic cases have been reported.^[5] Hence, in this study, we intended to compare the clinical efficacy of arthroscopy and conventional surgery in treating ischial tuberosity cysts in 49 cases between May 2016 and September 2018.

Material and methods

Inclusion and exclusion criteria

The inclusion criteria were as follows: patients with confirmed ischial tuberosity cysts by color Doppler ultrasound or magnetic resonance imaging (Fig. 1A and B); with obvious pain or tenderness, and who received conservative treatment for at least 6 weeks and that turned out to be ineffective; with unilateral ischial tuberosity cysts; and who were willing to participate in this study, and signed informed consent form. Exclusion criteria were as follows: patients with bilateral ischial tuberosity cysts; with a history of hormone injection for the treatment of ischial tuberosity cysts; had ischial tuberosity cyst infection as well as ulcers in the buttock and sacrococcygeal region; and with other underlying diseases and who were not tolerable to surgery. This study obtained approval from the ethics committee of the Ningbo First Hospital (No.2019-03-20). All patients gave written informed consent.

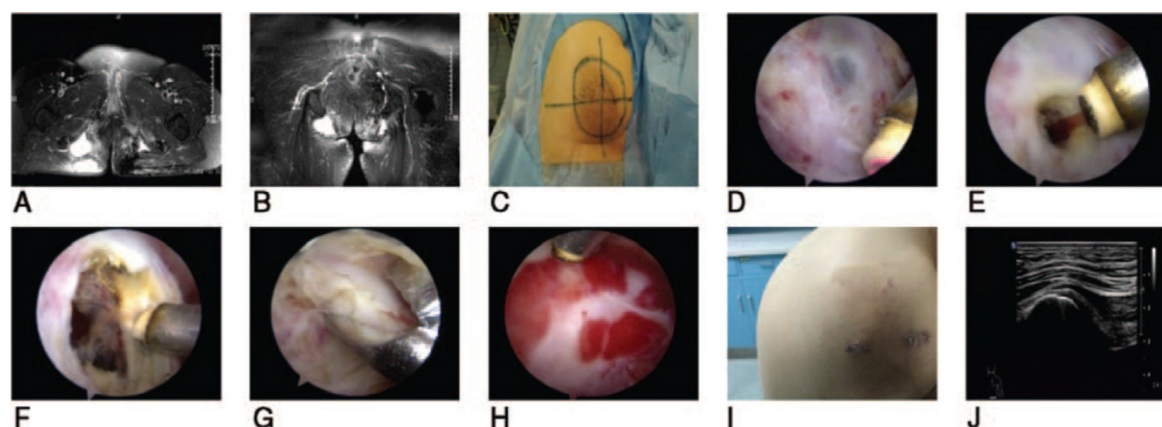


Figure 1.A 75-year-old female patient with right ischiogluteal cyst

A. Cross-sectional MRI image of the ischial tuberosity cyst showing separation of the right ischial tuberosity cyst. **B.** Coronal MRI image shows cystic changes of ischial tuberosity on the right side. **C.** The location of ischial tuberosity cyst before surgery was marked. **D.** A dissection along the surface

of the cyst was made to establish an operative space under an arthroscope, which showed a pale blue translucent cyst wall. **E.** Arthroscopic radiofrequency incision of the cyst showing brown bloody fluid flowing out. **F.** Arthroscopic radiofrequency gasification of the cyst wall. **G.** A basket punch was used to bite off the cyst wall under an arthroscope. **H.** Arthroscopic radiofrequency cleaning of the synovial layer of the ischial tuberosity cyst. **I.** The wound was well healed at 1 month after the arthroscopy surgery. **J.** Ultrasound image showed disappearance of the cyst 12 months after the arthroscopic surgery. MRI = magnetic resonance imaging.

Clinical data

The clinical data of 57 patients with ischial tuberosity cyst from May 2016 to September 2018 were retrospectively analyzed. According to the inclusion and exclusion criteria, a total of 49 patients with ischial tuberosity cysts were included. The arthroscopy group consisted of 24 patients, including 16 males and 8 females, with an average age of (64.1 ± 9.3) years (range: 42-81 years), and a disease course of (17.0 ± 9.1) months (range: 2~36 months). Ischial tuberosity was present on the left side in 11 cases, and on right side in 13 cases, and 5 cases had diabetes. The cyst diameter was (7.72 ± 1.71) cm. An operative space was constructed around the cyst, and the cyst wall was debrided during arthroscopy. The conventional incision group consisted of 25 patients, including 11 males and 14 females, with an average age of (61.2 ± 10.6) years (range: 47-79 years), and had a disease course of (17.5 ± 8.5) months (range: 4-36 months). Ischial tuberosity was present on the left in 11 cases, and on the right side in 14 cases, and 6 cases had diabetes. The cyst diameter was (7.69 ± 1.64) cm. Hence, the preoperative clinical data were comparable and showed no significant differences between the 2 groups ($P > .05$) (Table 1).

Table 1. Comparison of clinical data between arthroscopy group and conventional incision group

Group	Number of	Gender (n)		Age	Location (n)		Cyst diameter	Disease course	Diabetes(n)	
		M	F	($\bar{X} \pm S, \text{yr}$)	Left	Right	($\bar{X} \pm S, \text{cm}$)	($\bar{X} \pm S, \text{mo}$)	Yes	No
Arthroscopy group	24	16	8	64.1 ± 9.3	11	13	7.72 ± 1.71	17.0 ± 9.1	5	19
Conventional incision group	25	11	14	61.2 ± 10.6	11	14	7.69 ± 1.64	17.5 ± 8.5	6	19
Test value		$\chi^2 = 2.543$	=	$t = 1.001$	=	$\chi^2 = 0.017$	$t = 0.770$	$t = -0.192$	=	$\chi^2 = 0.071$
P value		.111		.322	.897		.939	.849	.791	

Surgical methods

Arthroscopy group

After epidural block anesthesia, the patient was placed in the prone position, with knees and hips flexed. Preoperative magnetic resonance imaging examination showed ischial tuberosity cysts,

and anatomical landmarks such as sciatic nerve, posterior superior iliac spine, and greater femoral trochanter were marked on it. After conventional sterilization and draping, the sketch of outline of the cyst was drawn, and the cyst was divided into 4 quadrants by drawing the abscissa and ordinate based on the center of the cyst (Fig. 1C). A 0.5 cm incision was separately made at the lateral superior and medial superior quadrants, which were 2 to 3 cm away from the center. A blunt puncture cone was then used to dissect the cyst surface to create a 4cm × 4 cm operative space, and an arthroscope was placed through this. The other inlet was considered as the working channel to place a shaver to debride the fibrous connective tissue on the surface of the cyst. After radiofrequency hemostasis, the ischial tuberosity cyst was exposed, which was light blue and translucent, with intact capsule (Fig. 1D). The cyst was then cut open by radiofrequency, causing bloody fluid that is dark brown in color flowing out (Fig. 1E). The arthroscope was inserted into the cyst to separate the cystic cavity, synovial hyperplasia and hemosiderin deposition. The capsule was completely removed using a shaver and radiofrequency (Fig. 1F). In cases with large cysts, the assistance of a basket punch was taken to remove the cyst wall in order to improve the operation efficiency (Fig. 1G). After incision of the surrounding cyst wall, the endometrium attached to the surface of the ischial tuberosity was exposed, and this was then removed by radiofrequency (Fig. 1H). After complete hemostasis, a negative pressure drainage tube was placed along the working channel, followed by suture incision and dressing. No epinephrine was added to the arthroscopic lavage fluid, and hemostatic drugs were not applied throughout the whole body during the surgical procedure.

Conventional incision group

The patient was given epidural block anesthesia, and was placed in prone position, with knees and hips flexed. After conventional sterilization and draping, the sketch of the outline of the cyst was drawn. A horizontal incision of about 6 cm in length was then made along the cleavage lines of the skin by considering the cyst as the center. The deep subcutaneous fascia was incised, and was bluntly dissected till the cystic surface. The incision could be appropriately expanded for larger cysts. Attention should be paid to protect the lateral sciatic nerve and medial rectal structures. Subsequently, the dense connective tissue on the cyst surface was dissected, and performed hemostasis, to completely remove the cyst from the ischial tuberosity. The residual cyst wall on the ischial tuberosity was cauterized. Finally, the incision site was rinsed, the drainage tube was dwelled, and the incision was sutured. No hemostatic medication was used systemically or locally during the procedure.

Postoperative treatment

After surgery, the patients were dressed with compression bandage, and were placed in supine and lateral positions alternately. They were given ice treatment within 24 hours. The drainage tube was removed at 48 hours after surgery or when the drainage was less than 10 mL/d. One day after surgery, the patients were given cefuroxime injection to prevent infection. They were allowed to leave the sickbed for appropriate activities in the early stage, with regular change of dressing.

Observation indicators and methods

The operation time, intraoperative blood loss, incision drainage, postoperative hospital stay, and postoperative complications were observed and compared between the 2 groups. Visual analogue score (VAS)^[6] was used to evaluate the degree of pain relief at 1 day, 1 week, and 1 month after surgery. The criteria are as follows: 0 point: no pain, 1 to 3 points: mild pain, 4 to 6 points: feel painful, which affects sleep, but still tolerable, and 7 to 10 points: severe pain, unbearable pain, which affects appetite, and sleep.

Statistical analysis

Statistical analyses were performed using SPSS19.0 software (Armonk, NY: IBM Corp). The measurement data were expressed as means \pm standard deviation ($X \pm S$). The test of normality using Shapiro-Wilk method was first performed on the data. Of these, data such as age, cyst size, disease course, intraoperative blood loss, and follow-up time were normally distributed with homogeneous variance. While operation time, VAS score, postoperative drainage and postoperative hospital stay were non-normally distributed and nonparametric tests were performed. Categorical data such as gender, cyst location, and incidence of postoperative complications were expressed as [(n%)], and performed 4-table Pearson chi-squared test. A difference of $P < .05$ was considered to be statistically significant.

Results

This study included 49 patients who underwent ischial tuberosity cyst procedures. Of these patients, 24 patients received arthroscopic procedure and 25 patients received conventional procedures. Demographic characteristics for both groups are included in Table 1. And no statistically significant difference was found between the 2 groups for any demographic characteristic or comorbidity. All 49 patients were followed up for 6~18 (11.3 ± 3.3) months, and patients in the arthroscopy group were followed up for 6~17 (10.9 ± 2.7) months, and those in the conventional incision group were followed up for 6~18 (11.7 ± 3.5) months. All patients in the arthroscopy group achieved phase I healing (Fig. 1I) and ultrasound image showed disappearance of the cyst 12 months after the arthroscopic surgery (Fig. 1J), while 3 patients in conventional incision group developed complications.

The clinical effect data are shown in Table 2, no difference in the follow-up duration and incidence of postoperative complications were noted between the 2 groups ($T = 1.765 P = .247$; $X^2 = 1.335 P = .248$). While, other parameters in the arthroscopy group were better than those in the conventional incision group: the mean operation time was 54.7 ± 7.7 minutes in arthroscopy group and 71.8 ± 8.8 minutes in the conventional incision group ($P < .001$). The mean intraoperative blood loss was 20.8 ± 3.5 mL in arthroscopy group and 67.3 ± 12.0 mL in the conventional incision group ($P < .001$). The mean postoperative incision drainage was 20.3 ± 5.6 mL in arthroscopy group and 103.6 ± 20.3 mL in the conventional incision group ($P < .001$). The mean postoperative hospital stay was 2.8 ± 0.6 days in arthroscopy group and 7.8 ± 2.9 days in the conventional incision group ($P < .001$). And the mean VAS pain scores at 1day, 1 week, and

1 month after surgery was 2.6 ± 0.7 , 0.5 ± 0.6 , 0.3 ± 0.5 , respectively in arthroscopy group and 6.0 ± 0.7 , 3.0 ± 1.0 , 1.1 ± 1.0 , respectively in the conventional incision group ($P < .001$).

Table 2. Comparison of the results between arthroscopy group and conventional incision group during and after surgery

Group	Number of cases	Operation time (min, x ± s)	Intraoperative blood loss (mL, x ± s)	Follow-up duration (m, x ± s)	VAS score			Postoperative drainage (mL, x ± s)	Hospital stay (d, x ± s)	Postoperative complications		
					1 d after surgery	1 wk after surgery	1 mo after surgery			Incision infection	Incision dehiscence	Relapse
Arthroscopy group	24	54.7 ± 7.7	20.8 ± 3.5	10.9 ± 2.7	2.6 ± 0.7	0.5 ± 0.6	0.3 ± 0.5	20.3 ± 5.6	2.8 ± 0.6	0	0	0
Conventional incision group	25	71.8 ± 8.8	67.3 ± 12.0	11.7 ± 3.5	6.0 ± 0.7	3.0 ± 1.0	1.1 ± 1.0	103.6 ± 20.3	7.8 ± 2.9	2	0	1
Statistics		-5.044	-18.140	1.765	-6.140	-5.955	-3.171	-5.950	-6.082	1.335		
P value		.000	.000	.247	.000	.000	.002	.000	.000	.248		

VAS = visual analogue score

Discussion

Anatomical characteristics of ischial tuberosity cysts

Ischial tuberosity bursa is located between the ischial tuberosity and the gluteus maximus, and it belonged to the normal latent bursa of the human body, which can reduce the friction between tissues and protect the ischium. In elderly patients, the muscles and ligament tissues are atrophied, their constitution is thin, and had reduced subcutaneous fat. Under some special circumstances, such as long time bending in desk jobs, sedentariness, improper compression, trauma, etc., the repeated friction at the sciatic area and inflammation leads to hyperemia and increases serous exudate in the ischial tuberosity bursa. After a long time, the effusion becomes thick and turbid, and adheres to the deposited cellulose, resulting in thickened bursal wall, and rough synovial surface.^[1,7] Ischial tuberosity cysts are more commonly observed in elderly women, and more commonly occur on one side, which might be due to the imbalanced load on

bilateral ischium. If the content of the cysts is dark brown bloody fluid, then it refers to a thin cyst wall and short onset time, while if the content of the cysts is pale yellow liquid, then it refers to a thick cyst wall and long onset time.

Feasibility of arthroscopy for treating ischial tuberosity cysts

The rapid development of arthroscopic surgery in recent years has provided us with the possibility of minimally invasive treatment under the guidance of an arthroscope for ischial tuberosity cysts. Previous studies have reported the use of arthroscopy for treating extra-articular diseases, which provided valuable inspiration and experience for the present study. Liu et al^[8] have applied arthroscopy for treating gluteal muscle contraction, popliteal cyst, carpal tunnel syndrome, tennis elbow, torticollis and internal fixator removal, and achieved good results. There are several studies that reported the use of arthroscopy for treating nonjoint diseases such as enthesitis, and achieved satisfactory results.^[9,10] The anatomical structures around the ischial tuberosity cyst are clearly stratified, which remains conducive for constructing an operative space on the cyst surface. The possibility to create an effective operative space is the key to the success of arthroscopy for treatment of this type of disease. The ischial tuberosity cyst is located on the surface of the ischial tuberosity and deep gluteus maximus, with clear anatomical layers, and provides very good anatomical conditions for arthroscopy. Arthroscopy for the treatment of ischial tuberosity cyst remains to be safe. There are no important vascular and nerve structures within the scope of ischial tuberosity cyst surgery. The sciatic nerve exits the pelvic cavity from the inferior foramen of the piriformis, runs into the deep gluteus maximus, and travels distally through the midline of the femur greater trochanter and the ischial tuberosity. Imaging anatomy^[11,12] revealed that the average distance from the sciatic nerve to the lateral cyst wall was 5.4 cm.

Comparison of efficacy between the arthroscopy group and the conventional incision group for the treatment of ischial tuberosity cysts

According to the literature,^[13-15] the treatment methods for ischial tuberosity cyst included intra-cystic hormone injection, platelet-rich plasma injection, surgical resection, etc. Among these, the injection method has a high recurrence rate, and the risk of local infection, exudate, etc., making it difficult for subsequent treatment. Therefore, for patients with ischial tuberosity cysts and obvious symptoms, clinical surgery is still regarded as the major treatment method.^[13] Nonetheless, due to special location of the ischial tuberosity cyst, there are still many complications after conventional incision surgery. Based on the development of arthroscopic techniques and cognition of the anatomical characteristics of ischial tuberosity cyst, all 49 patients were divided into arthroscopy group and conventional incision group to compare the therapeutic effects, and summarized the pros and cons of the 2 surgical methods. Arthroscopy is characterized by minimal trauma and clear vision during the treatment of ischial tuberosity cysts. Long-term repeated friction of the sciatic area leads to local chronic inflammation and hyperplasia of the cyst, and forms dense fibrous tissue, and this makes it difficult to expose. The incision surgery tends to be associated with large amounts of intraoperative bleeding and large trauma, and sometimes is difficult to achieve complete resection, resulting in postoperative recurrence. Meanwhile, arthroscopy completely exposes the cyst, and removes the entire cyst

under direct vision. The statistics of the present study showed that the intraoperative blood loss and postoperative drainage in arthroscopy group were significantly better than those in the conventional incision group ($P < .001$). Patients rapidly recover after undergoing arthroscopy for the treatment of ischial tuberosity cysts. Statistical results of the present study revealed that the postoperative VAS score and postoperative hospital stay in patients in the arthroscopy group were significantly better than those in the conventional incision group ($P < .001$). The patients in the arthroscopy group had smaller trauma, less tissue dissection, milder inflammatory response of local tissues, and milder postoperative pain, which are conducive to postoperative recovery. Postoperative complications of the 2 groups are subjected to large sample studies. In the present study, 2 patients developed incision infection and 1 case relapsed after surgery in the conventional incision group, and no cases in the arthroscopy group had postoperative complications. However, statistical analysis revealed no significant differences in the incidence of complications between the 2 groups ($P > .05$). This might be due to the small sample size and short follow-up duration. Hence, the incidence of postoperative complications requires conduction of further studies on larger sample size and longer follow-up duration. Arthroscopy for treating ischial tuberosity cyst requires operating skills. In the present study, the operation time in the arthroscopy group was significantly shorter than that in the conventional incision group ($P < .05$), indicating that the arthroscopy is not difficult in terms of operation and orthopedists with basic arthroscopic skills can implement it.

Experience of arthroscopy for the treatment of ischial tuberosity cyst

The experiences of arthroscopy for the treatment of ischial tuberosity cysts were as follows: In view of the great motion of the ischial tuberosity cyst and the lack of effective reference after draping, it is necessary to mark the cyst location and important body surface structures before surgery. A coordinate can be established based on the center of the cyst to divide the cyst into 4 quadrants. The lateral and medial approaches can be created 2 to 3 cm away from the center of the cyst, and can be adjusted appropriately according to the size of the cyst. An operative space is created in an outside-in manner on the cyst surface with a blunt puncture cone, which can be enlarged by radiofrequency hemostasis to reveal the pale blue translucent cyst wall. This is different from that of the inside-out resection method, in which the cyst wall penetrates into the cystic cavity. The inside-out method has requirements of cyst diameter, and is difficult to implement for cysts that are smaller in size or larger in motion. At the same time, arthroscopy insertion into the cyst is not conducive to observe the entire cyst. Methods to get a good vision: moderately increases the perfusion pressure; add 1 mg of epinephrine to every 3 L of perfusion to assist hemostasis; and use radiofrequency and shaver alternately, and radiofrequency-assisted hemostasis has the unique advantage to allow the use of low negative pressure planning throughout the process. To prevent cyst recurrence, the cyst wall is completely removed under arthroscopy surveillance. For cyst wall attached to ischial tuberosity, the inner synovial layer of the cyst (the synovial tissue is one of the key factors for cyst relapse) is cleaned by radiofrequency. In arthroscopy, the operation is performed by considering cyst as the center. When dealing with lateral and medial walls of larger cysts, special attention must be paid to the sciatic nerve and rectal wall. Hence, it is very important to be familiar with the anatomy as well as nerves and smooth muscle tissues associated during arthroscopy. At the same time, with a

good view under an arthroscope, arthroscopic cyst removal is considered to be very safe generally. In the present study, no case had sciatic nerve and rectal injuries. After cyst removal, the residual cystic cavity can be sealed by negative pressure suction using a drainage tube that is placed through the inlet of an arthroscope, which in turn reduces the complications such as hepatoma and postoperative swelling.

This study has several limitations. First, the limitations of this study involve the retrospective nature of the series and the short follow-up time, a prospective study with long-term evaluation would be necessary to define the best management strategies. Second, this study is a single center study with small case number, we will conduct a multi-center study and recruit more patients in the future.

Conclusions

The study showed that multiple indicators for clinical outcomes of arthroscopy were significantly better than those of conventional incision surgery in treating ischial tuberosity cyst. Arthroscopy has advantages of minimal invasion, less blood loss, milder postoperative pain, and rapid recovery compared with conventional incision surgery.

References

1. Miller RHI, Azar FM, Throckmorton TW. in Campbell's Operative Orthopedics. New York: Elsevier. 2012, 3. (853).
2. Saremi H, Seydan MA, Seifrabiei MA. Midterm results of arthroscopic treatment for recalcitrant lateral epicondylitis of the elbow. Arch Bone Jt Surg 2020; 8:184-9.
3. May O. Arthroscopic techniques for treating ilio-psoas tendinopathy after hip arthroplasty. Orthop Traumatol Surg Res 2019; 105(1S):S177-85.
4. Zhang B, Tao T, Li Y, Jiang Y, et al. Clinical analysis of autogenous tendon reconstruction under total arthroscopy in treatment of chronic Achilles tendon rupture. zhongguo Xiu Fu Chong Jian Wai Ke Za Zhi 2020; 34:726-9.
5. Zeng GL, Tang L. Arthroscopic treatment for 18 ischial tuberosity cysts. Chin J Mini Surg 2013; 13: 569572.
6. Ohnhaus EE, Adier R. Methodological problems in the measurement of pain: a comparison between the rating scale and the visual analogue scale. Pain 1975; 1:379-84.
7. Johnson DB, Varacallo M. Ischial bursitis. In: StatPearls [Internet]. Treasure Island (FL): StatPearls Publishing. 2020, 3. (15)
8. Liu YJ, Wang ZG, Wang JL, et al. Clinical classification of gluteal muscle contracture under arthroscopy. Chin J of Orthop Trauma 2013; 26: 468-70.
9. Lee DW, Kim JG, Kim TM, et al. Refractory patellar tendinopathy treated by arthroscopic decortication of the inferior patellar pole in athletes: mid-term outcome. Knee 2018;25:499-506.
10. Wang WK, Chen J, Lou JX, et al. Comparison of arthroscopic debridement and open debridement in the management of lateral epicondylitis: a systematic review and meta-analysis. Medicine 2019;98:e17668.

11. Yang XX, Hao W, Fang LQ. Ultrasound manifestation of ischial tuberosity cysts. *Chin J Ultrasound* 2007; 4: 313.
12. Akisue T, Yamamoto T, Marui T, et al. Ischiogluteal bursitis: multimodality imaging findings. *Clin Orthop Relat Res* 2003; 214-7.
13. Li WY, Zhou YP, Wang LC. Injectional treatment for recurrent ischial tuberosity cysts. *Chin J Gen Surg* 2011; 20:323-4.
14. Shen ZW, Lin ZH, Zhen QJ, et al. Platelet-rich plasma for treatment of ischiogluteal bursitis. *Chin J o Tissue Eng Res* 2014; 18:7689-96.
15. Shen ZD, Gong ZY. Surgical explore of ischial tuberosity cysts. *Suzhou Univ J Med Sci* 1999; 19: 815.